




## DIET FACTOR

Journal of Nutritional & Food Sciences  
<https://www.dietfactor.com.pk/index.php/df>  
 Volume 1, Issue 2 (Jul-Dec 2020)



### Review Article

# Pathology and Epidemiology of Oral Squamous Cell Carcinoma

Hina Asif<sup>1</sup>, Ali Junaid Dar<sup>2</sup>, Muhammad Omer Pasha<sup>3</sup>, Akash John<sup>4</sup> and Neelam Iqbal<sup>5</sup>

<sup>1</sup>Shukat Khanum Memorial Cancer Hospital, Lahore, Pakistan

<sup>2</sup>University Institute of Radiological & Imaging Sciences, Faculty of Allied Health Science, The University of Lahore, Lahore, Pakistan

<sup>3</sup>Department of Medicine, Lahore General Hospital, Lahore, Pakistan

<sup>4</sup>University Institute of Radiological & Imaging Sciences, The University of Lahore, Gujrat Campus, Gujrat, Pakistan

<sup>5</sup>Institute of Molecular Biology and Biotechnology, The University of Lahore, Lahore, Pakistan

**Keywords:** Oral squamous cell carcinoma, oral cancer, substance abuse, smoking, pan

#### How to Cite:

Asif, H., Dar, A. J., Pasha, M. O., John, A., & Iqbal, N. (2020). Pathology and Epidemiology of Oral Squamous Cell Carcinoma. *DIET FACTOR (Journal of Nutritional & Food Sciences)*, 1(02). <https://doi.org/10.54393/df.v1i02.14>

#### Corresponding author:

Hina Asif  
 Shukat Khanum Memorial Cancer Hospital, Lahore, Pakistan  
[hinaasif657@gmail.com](mailto:hinaasif657@gmail.com)

#### Article History

Received: 2<sup>nd</sup> August 2020  
 Accepted: 5<sup>th</sup> September 2020  
 Published: 30<sup>th</sup> December 2020

### ABSTRACT

Oral Squamous Cell Carcinoma (OSCC) is the epithelial tumor of oral cavity and is the most common malignant tumor among all. Oral Squamous Cell Carcinoma (OSCC) is more existing and occurring in old men. It may involve lip and internal structures and may show clearly with exophytic, endophytic, leukoplakic or erythroplakic act of appearing. Occurrence of oral squamous cell carcinoma is in mouth, lip, tongue, floor of the mouth, Sulcus, hard palate, tonsils and 95% squamous cells. There is low survival rate have reported in females, ascribed to delay in availing medical care and seeking less acceptance of treatment, although there are no predictive differences between males and females.

## INTRODUCTION

Oral and oropharyngeal squamous cell carcinoma comprehends 3% in men and 2% of total cancers in women. The rate of loss of life on large scale and number of deaths in a given period is 2% and 1% for men and women respectively. The clinical presentation in a classical way of head and neck squamous cell carcinoma is a shallow ulcer with heaped-up-edges, often covered by a plaque. The greater inducers (a molecule that starts gene expression) of OSCC are all the forms of tobacco including smoked and smokeless. Since the last many decades, the survival rates of OSCC have not improved and creating a disappointing situation [1].

Cancer is one of the most causes of loss of life on large scale globally, with more than 6 million deaths and more than 10 million new cases [2]. OSCC comes under the main heading of HNSCC and HNSCC are like such diseases which are assuming alarming proportions in the world. In Pakistan, 90% include squamous cell carcinoma [3]. It ranks from the sixth to eighth most common cancer worldwide and its incidence is greatly varied and adapted among different countries [4]. Cancer of head and neck is a destructive disease accounting for 3% of all malignancies with an estimated 37,200 new cases and 1100 deaths every year in the United States [5]. Worldwide, the incidence of oral cancer is nearly 615,000 cases yearly [6] and 75,000 in the United States [7]. Squamous cell carcinoma (SCC or SqCC) is a kind of epithelial cell cancer, which is known as the squamous cell. More than 90% of all the cancers of head and neck are squamous cell carcinomas (HNSCC) and OSCC is included in head and neck squamous cell carcinomas. OSCC is one of the common carcinomas and malignancies in the maxillofacial and oral regions and it is the sixth most common cause of cancer that leads to death worldwide [8].

The mutual relation between age and prognosis seems to give controversy and disputation and some authors show that there is no correlation between them while others show evidence of very bad prognosis in older patients [9]. Another feasible theory that can exist is that those patients develop symptoms earlier who have unfriendly hostile tumors, so they avail



medical considerations and health attentions sooner, despite these patients still have to face worse and serious results. The outcomes can be more grievous and dangerous, because these malignancies cause a more offensive and self-assertive biologic behavior [10]. The essential part of tumor formation is the new blood vessels being formed. The formation of new blood vessels occurs as the OSCC grows and assails. This is a multi-step process that is regulated by inhibitory and stimulatory factors. This mechanism is known as the neovascularization [11,12].

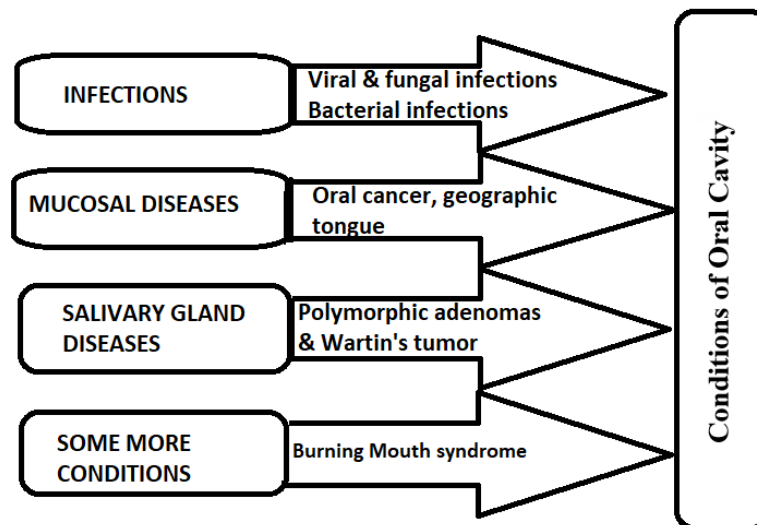
### Oral Cavity-Anatomy and Pathology:

The oral cavity consists of the vestibule and the oral cavity proper. It is bounded externally by the cheeks and lips. Palate forms the roof of the oral cavity. The oral cavity connects with the oropharynx at posterior. The oral cavity and oropharynx comprehend the upper portion of the digestive tract. The differentiation of the pathologic processes in prognosis, presentations and grades of histology makes oral cavity and oropharynx distinguished from each other [13].

SITE	PERCENTAGE
LOWER LIP	35%
VENTRAL/LATERAL TONGUE	25%
FLOOR OF MOUTH	20%
SOFT PALATE	15%
GINGIVA/ALVEULAR RIDGE	04%
BUCCAL MUCOSA	01%

**Table 1:** Estimated Percentages of Sites for OSCC

According to sites, there is a general clinical distribution of OSCC. The table 1 shows us the approximate percentages of cancer progression in the specific site of oral cavity. We need to carefully examine the tongue of patient and the floor of the mouth. Mostly, the common site of tumor is lateral tongue. The lower lip is considered by some a skin site because it is exposed to actinic radiation and therefore has a separate co-factor that promotes growth of cancer.



**Figure 1:** Conditions of oral cavity

According to sites, there is a general clinical distribution of oral squamous cell carcinoma Conditions of oral cavity are depicted in figure 1. The table 1 shows us the approximate percentages of cancer progression in the specific site of oral cavity. We need to carefully examine the tongue of patient and the floor of the mouth. Mostly, the common site of tumor is lateral tongue. The lower lip is considered by some a skin site because it is exposed to actinic radiation and therefore has a separate co-factor that promotes growth of cancer.

The field of oral & maxillofacial pathology is progressing day by day with the technological advances in the recent years [14]. Estimation, rise in value & recognition of the clinicopathological characteristics should facilitate an appreciation that the anatomy, physiology, growth or relationship of the structures of maxillofacial region may have been altered by the pathological entity or treatment received [15].

Oral pathology is related to oral medicine, oral & maxillofacial surgery and oral surgery. Oral pathology is the field which involves the study of the diseases of oral and maxillofacial areas and the causes and effects of these diseases [16]. An essential principle is to establish, usually by biopsy, the pathological nature of any lesion suspected of being neoplastic. The first distinction to be made is between benign and malignant lesions [17,18].

### **Epidemiology and Etiology:**

In Pakistan, the second most common cancer in males is oral cancer. In developed and developing countries, the incidence & prevalence of oral cancer is highest and increasing fastly [19]. In epidemiology & etiology of oral squamous cell carcinoma, the increasing rates of incidence & mortality has been observed. In men, the incidence rate is 6.6/100,000 while in women it is 2.9/100,000. The mortality rate of OSCC is 3.1/100,000 in men and 1.4/100,000 in women. The incidence and mortality rates related to OSCC is higher in men than in women [20]. In Karachi, increasing prevalence rates have been observed, along with some specific areas of Punjab and Sindh. In Punjab, highest rates have been noticed in Multan and in the case of Sindh it is observed in Jamshoro and much lesser frequency in North West Frontier Province [21]. Increase of considerable amount in rates of mortality have been noticed in most areas of eastern Europe especially in males of young age [22].

There is low survival rate have reported in females, ascribed to delay in availing medical care and seeking less acceptance of treatment, although there are no predictive differences between males and females [23]. The mutual relation between age and prognosis seems to give controversy and disputation and some authors show that there is no correlation between them while others show evidence of very bad prognosis in older patients [9]. Another feasible theory that can exist is that those patients develop symptoms earlier who have unfriendly hostile tumors, so they avail medical considerations and health attentions sooner, despite these patients still have to face worse and serious results. The outcomes can be more grievous and dangerous, because these malignancies cause a more offensive and self-assertive biologic behavior [10]. The essential part of tumor formation is the new blood vessels being formed. The formation of new blood vessels occurs as the OSCC grows and assail. This is a multi-step process that is regulated by inhibitory and stimulatory factors. This mechanism is known as the neovascularization [11].

### **REFERENCES**

1. Hunter KD, Parkinson EK *et al.* Profiling early head and neck cancer. *Nat Rev Cancer* 2005, 5(2): 127-135. doi: 10.1038/nrc1549.
2. Bose KS, Gokhale PV *et al.* Quantitative evaluation and correlation of serum glycoconjugates: Protein bound hexoses, sialic acid and fucose in leukoplakia, oral sub mucous fibrosis and oral cancer. *J Nat Sci Biol Med*, 2013, 4(1): 122-125. doi: 10.4103/0976-9668.107275.
3. White AC, Tran K *et al.* Defining the origins of Ras/p53-mediated squamous cell carcinoma. *Proc Natl Acad Sci U S A*, 2011, 108(18): 7425-7430. doi: 10.1073/pnas.1012670108.
4. Scully C and Bedi R. Ethnicity and oral cancer. *Lancet Oncol*,2000, 1(1): 37-42. doi: 10.1016/S1470-2045(00)00008-5.
5. Rusthoven KE, Raben D *et al.* Improved survival in patients with Stage III-IV Head and neck cancer treated with radiotherapy as primary local treatment modality. *Int J Radiat Oncol Biol Phys*,2008, 72(2): 343-350. doi: 10.1016/j.ijrobp.2007.12.046.
6. Mignogna MD, Fedele S *et al.* The World Cancer Report and the burden of oral cancer. *Eur J Cancer Prev*,2004, 13(2): 139-142. doi: 10.1097/00008469-200404000-00008.
7. Davies L and Welch HG. Epidemiology of head and neck cancer in the United States. *Otolaryngol Head Neck Surg*,2006, 135(3): 451-457. doi: 10.1016/j.otohns.2006.01.029.
8. Li SY, Hu JA *et al.* Expression of Yes-associated protein 1 gene and protein in oral squamous cell carcinoma. *Chin Med J (Engl)*, 2013, 126(4): 655-658.
9. de Cassia Braga Ribeiro K, Kowalski LP *et al.* Perioperative complications, comorbidities, and survival in oral or oropharyngeal cancer. *Arch Otolaryngol Head Neck Surg*,2003, 129(2): 219-228. doi: 10.1001/archotol.129.2.219.
10. Allison P, Locker D *et al.* The role of diagnostic delays in the prognosis of oral cancer: a review of the literature. *Oral Oncol*,1998, 34(3): 161-170. doi: 10.1016/s1368-8375(97)00071-7.
11. Bergers G and LE. Benjamin. Tumorigenesis and the angiogenic switch. *Nat Rev Cancer*, 2003, 3(6): 401-410. doi: 10.1038/nrc1093.

12. Michailidou EZ, Markopoulos AK *et al.* Mast cells and angiogenesis in oral malignant and premalignant lesions. *Open Dent J*, 2008, 2: 126-132. doi: 10.2174/1874210600802010126.
13. Laine FJ and Smoker WR. Oral cavity: anatomy and pathology. *Semin Ultrasound CT MR*, 1995,16(6): 527-545. doi: 10.2174/1874210600802010126.
14. Tandon R and Herford AS. Future of bone pathology, bone grafting, and osseointegration in oral and maxillofacial surgery: how applying optical advancements can help both fields. *J Biomed Opt*,2013, 18(5): 55006. doi: 10.1117/1.JBO.18.5.055006.
15. Brierley DJ, Chee CK *et al.* A review of paediatric oral and maxillofacial pathology. *Int J Paediatr Dent*. 2013. doi: 10.1111/ipd.12029.
16. Neville BW and Day TA. Oral cancer and precancerous lesions. *CA Cancer J Clin*, 2000, 52(4): 195-215. doi: 10.3322/canjclin.52.4.195.
17. Dolinsky H and Laifook M. Oral pathology quiz #32. Case 2. Benign salivary gland tumor. *J N J Dent Assoc*, 2001, 72(2): 32-33, 36.
18. Ozturk O and Tutkun A. A case report of a malignant peripheral nerve sheath tumor of the oral cavity in neurofibromatosis type 1. *Case Rep Otolaryngol*, 2012: 936735. doi: 10.1155/2012/936735
19. Ali TS and Baig S. Evaluation of a cancer awareness campaign: experience with a selected population in Karachi. *Asian Pac J Cancer Prev*, 2006, 7(3): 391-395.
20. Landis SH, Murray T *et al.* Cancer statistics, 1999. *CA Cancer J Clin*, 1999, 49(1): 8-31, 31. doi: 10.3322/canjclin.49.1.8.
21. Chaudhry S, Khan AA *et al.* Estimating the burden of head and neck cancers in the public health sector of Pakistan. *Asian Pac J Cancer Prev*, 2008, 9(3): 529-532.
22. La Vecchia C, Tavani A *et al.* Epidemiology and prevention of oral cancer. *Oral Oncol*, 1997, 33(5): 302-312. doi: 10.1016/s1368-8375(97)00029-8.
23. Al-Rajhi N, Khafaga Y *et al.* Early stage carcinoma of oral tongue: prognostic factors for local control and survival. *Oral Oncol*, 2000, 36(6): 508-514.